

بِسْمِ اللّٰهِ الرَّحْمٰنِ الرَّحِیْمِ

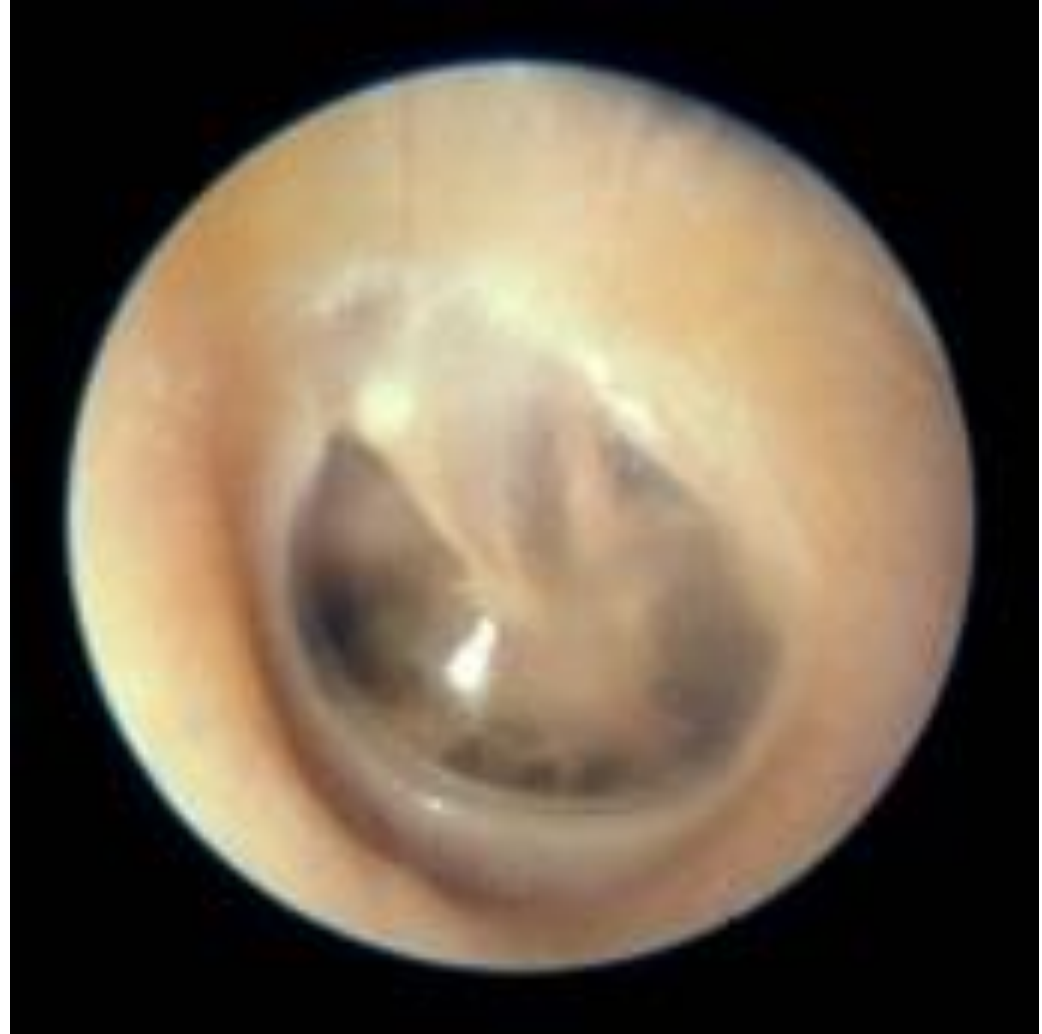ACUTE OTITIS MEDIA

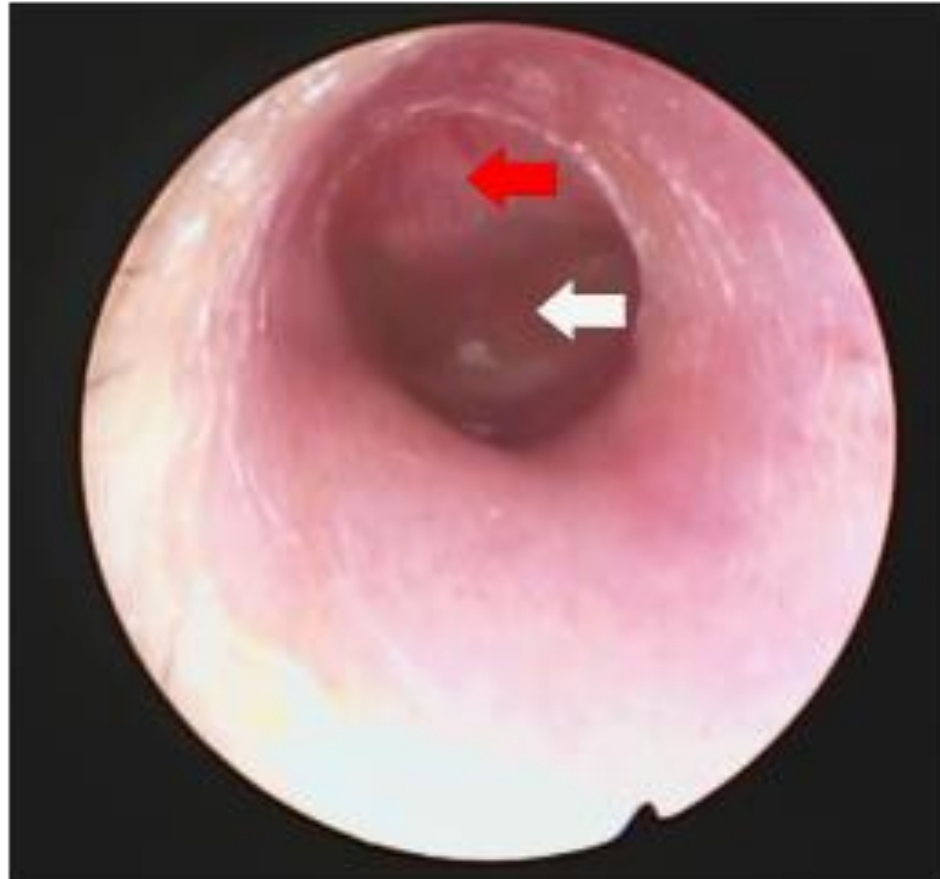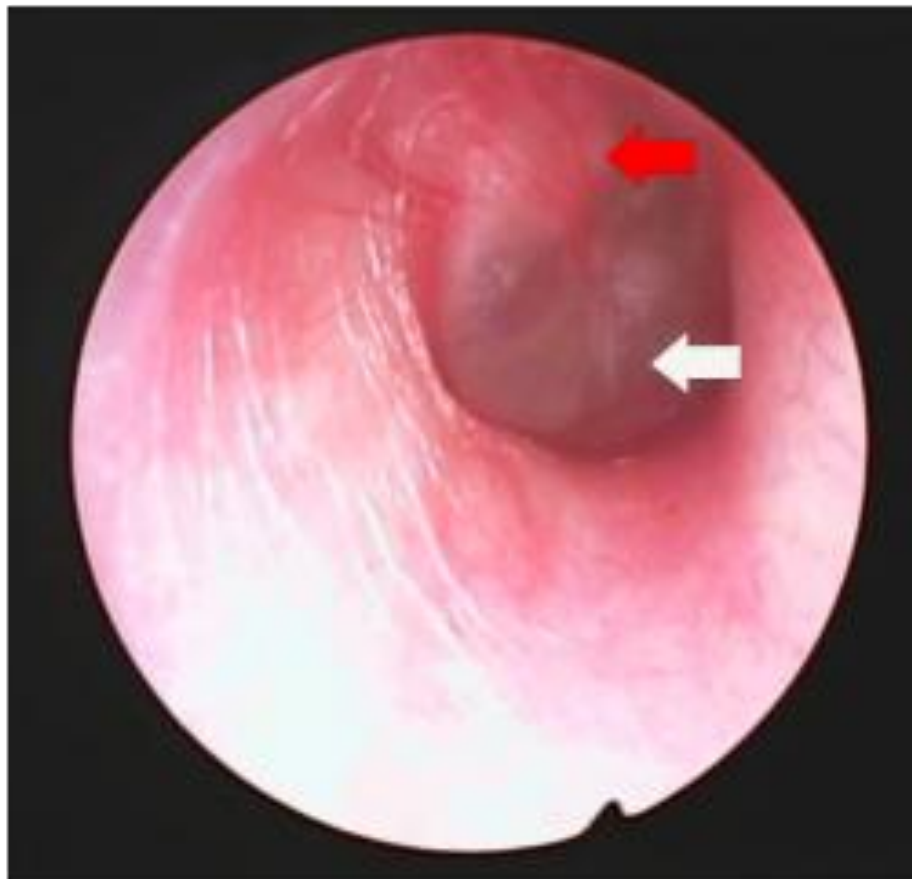**ILLUSTRATIVE IMAGES FOR OTOSCOPIC
FINDINGS**

PRESENTED TO 4TH YEAR MEDICAL STUDENTS

Normal TM

- Pearly grey color with luster
- Semi-translucent
- Oblique position forming 55 degree angle with the antero-inferior wall of external canal and results in appearance of cone of light on otoscopic examination





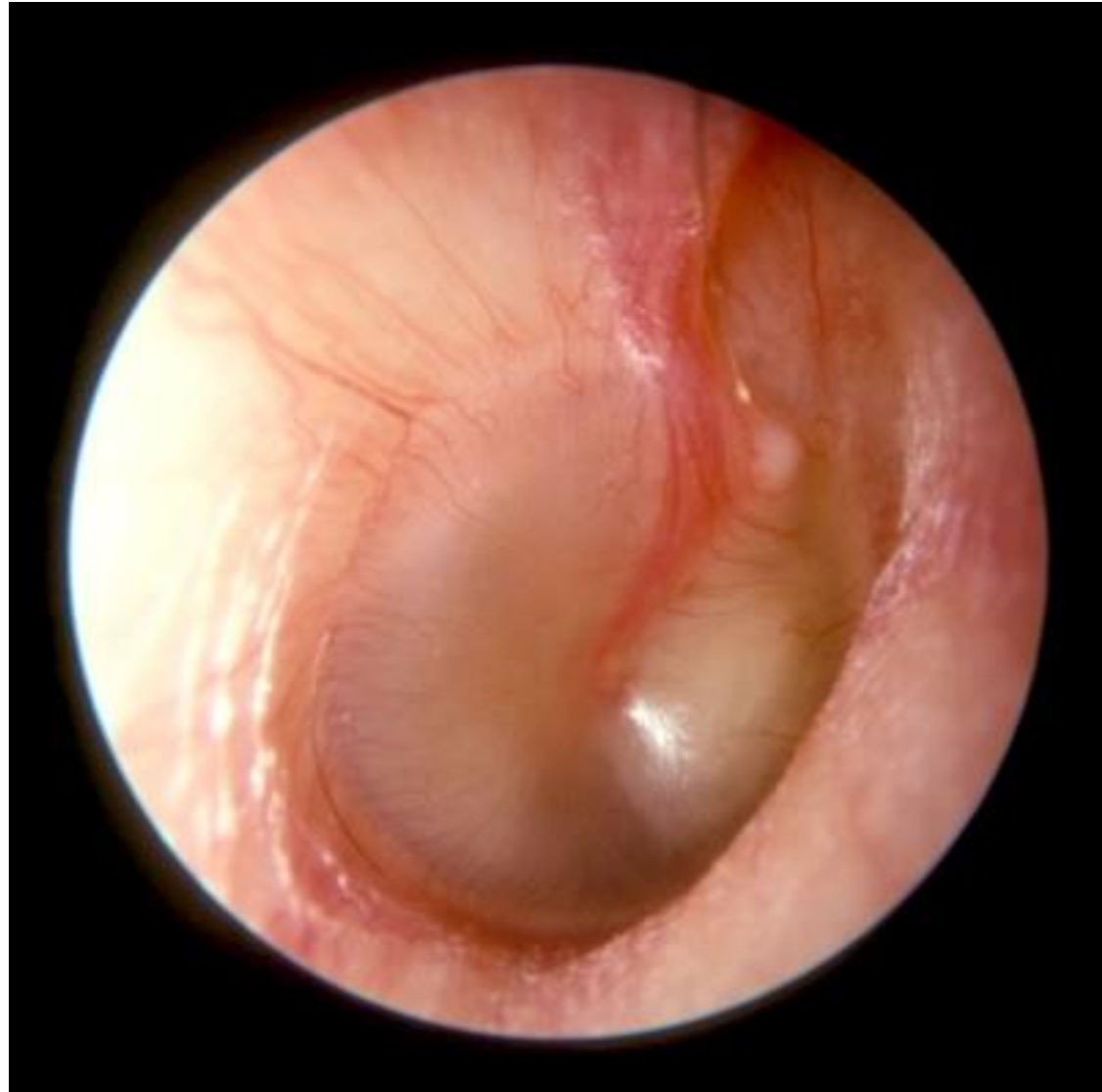Acute otitis media -notice the more prominent vessels (red arrows) and the dull-looking eardrum (white arrows) signifying fluid behind the ear drum. Compare that to the normal translucent ear drum above.

© Vincent Tan ENT

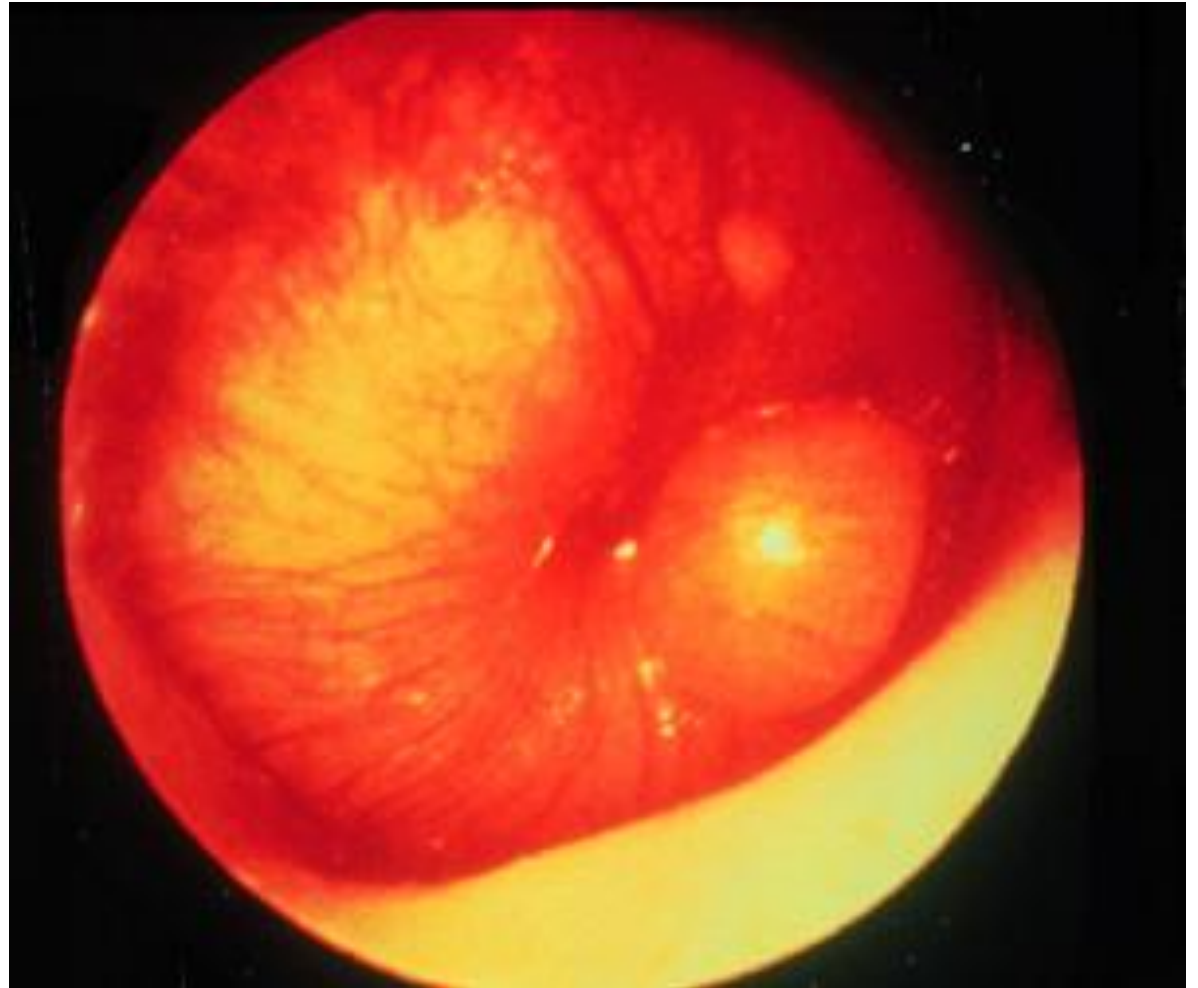
Acute Otitis Media

Catarrhal stage

Congested vessels on the handle of Malleus and periphery of the TM



Acute Otitis Media
Suppurative stage
Bulging TM



Acute Otitis Media
Stage of perforation
Discharging ear



